



**PATIENT**

Kona Stephens

**SPECIES**

Feline

**BREED**

DSH

**SEX**

Male Neutered

**AGE**

12 years

**WEIGHT**

10.6lbs

**INTERPRETED BY**

Maggie Machen  
 Lamy, DVM, DACVIM  
 (Cardiology)

**IMAGING PERFORMED BY**

Jenna Walsh, CVT

**HOSPITAL NAME**

The Veterinary  
 Hospital

**REFERRING VET**

Dr. Yamanda

**INVOICE**

26492

**DATE**

9/21/22

**PRESENTING CLINICAL SIGNS**

History: Presented to ER for dyspnea. Nonspecific CXR results. Grade 3/6 murmur was detected on 8/1/22 exam. He has been asymptomatic but had persistently high BP (120 - 150 systolic with 60 - 100 MAP) throughout dental procedure. BP at rest during dental recheck was 158/129 (142), 147/124 (134), 176/142 (158), 153/123 (134), 158/123 (132).

-Abnormal PE/Chem/CBC/UA Results: Senior panel 7/22/22- CBC - WNLs, good hemogram/slight leukopenia 5.32k with monocytopenia 0.04k/thrombogram Comprehensive Plus - WNLs; good renal/hepatic/pancreatic function. Stress hyperglycemia 137 Lytes - WNLs T4 - WNLs at 2.2 SDMA - WNLs at 9 UA - WNLs - USG 1.024, pH 5.0, pro/gluc/ket/ubg neg, bil/bld neg. WBC/RBC <1/HPF, no bacteria/casts/crystals seen on manual or sedivue. Bladder was ultrasonographically normal on cysto

**ELECTROCARDIOGRAPHIC FINDINGS** \*Note: Single lead ECGs are evaluated as a rhythm strip. Morphology/MEA cannot be definitively commented on.

A single lead ECG is available; 50mm/s, 20mm/mV. The average heart rate is 150bpm with a largely regular rhythm. The rhythm is sinus in origin, with a p for every QRS complex and vice versa. The P morphology is positive. The QRS is isoelectric. No ectopic beats, pauses or dysrhythmias observed.

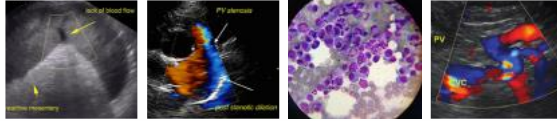
ECG diagnosis: Normal sinus rhythm.

**ECHOCARDIOGRAM FINDINGS**

2D, m-mode, color flow and doppler imaging is available. The left ventricular wall is normal in dimension. There is a diffusely hyperechoic endocardium consistent with age-related fibrosis. Minimal remodeling. The papillary muscles are hyperechoic. The left atrium is normal in size. The right atrium is normal in size. The right ventricle appears normal. The mitral valve is normal in structure and mobility. Trivial MR. The tricuspid valve appears normal in structure and mobility. Trivial TR. Blood flow through both the LVOT and RVOT are normal in velocity. No effusions. No obvious cardiac tumors.

**CARDIAC CHART**

FELINE CARDIAC PARAMETERS	BODY WEIGHT (kg)	HR (BPM)	IVSd (cm) (Moise, Pipers)	LVIDd (cm) (Moise, Pipers)	LWVd (cm) (Moise, Pipers)	FS (%)	EF (%)
NORMAL PARAMETER	-----	150-240	0.35-0.55	<2 (mean 1.5)	3.5-0.55	35-67	80-100
PATIENT	4.8	NM	0.42	1.4	0.47	58	90
FELINE CARDIAC PARAMETERS	LA/AO (Boon)	LA/AO HEART BASE (Swe) (Abbott)	LA 2D short axis Base view (cm) (Abbott)		LVOT VEL (m/s)	RVOT VEL (m/s)	E max (m/s)
NORMAL	<1.5	<1.3	<1.2		<1.6	<1.3	<0.9
PATIENT	NM	1.1	1.1		0.9	1.0	NM
*Note: All measurements based upon multi-modal images and methods. An average value is reported. Adapted from June Boon, Veterinary Echocardiography, 1998 Abbott J & MacLean H JVIM 2006;20: 111-119, Moise et al. Am J Vet Res 47:1476, 1986. Pipers et al. Am J Vet Res 40:882, 1979.							



**PATIENT**

Kona Stephens

**SPECIES**

Feline

**BREED**

DSH

**SEX**

Male Neutered

**AGE**

12 years

**WEIGHT**

10.6lbs

**INTERPRETED BY**

Maggie Machen Lamy, DVM, DACVIM (Cardiology)

**IMAGING PERFORMED BY**

Jenna Walsh, CVT

**HOSPITAL NAME**

The Veterinary Hospital

**REFERRING VET**

Dr. Yamanda

**INVOICE**

26492

**DATE**

9/21/22

**INTERPRETATION OF THE FINDINGS & FURTHER RECOMMENDATIONS**

Overtly normal geriatric cardiac structure and function. Mild fibrosis of the left ventricular wall is noted, which is likely a normal age-related variant. No significant valve leaks are noted, and flow through the great vessels is normal in velocity. No definitive cause is identified for the murmur in this study, making it likely physiologic in origin (i.e., secondary to tachycardia, volume changes, etc.). Given these findings and a normal LA dimension, no medications are indicated.

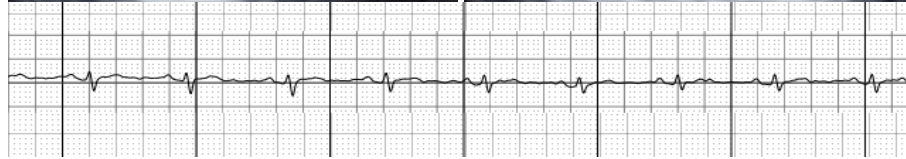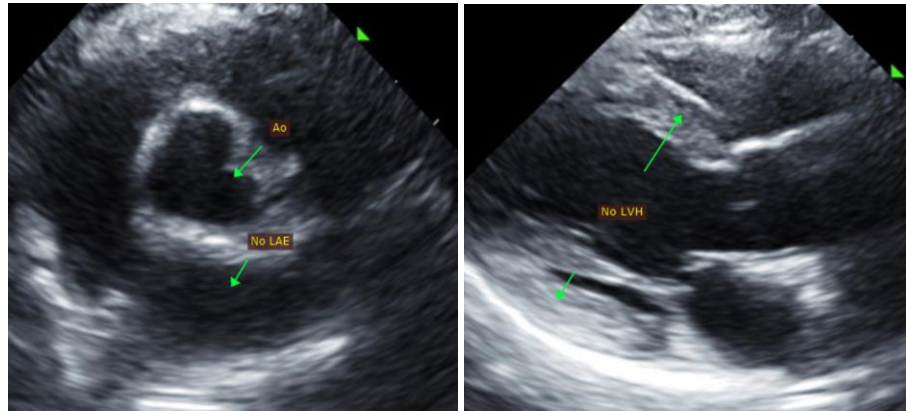
These findings would certainly suggest the respiratory changes are noncardiac in origin. The ECG is unremarkable with a normal sinus rhythm.

No cardiac contraindication for general anesthesia. Should fluid or steroid therapy be indicated in the future, any cat should be monitored for intolerance (changes in RR/RE).

Monitor at home for signs of cardiac compromise, including respiratory changes and/or signs of a blood clot event (paralysis, neurologic changes).

Recommend recheck echocardiogram in 1 year to assess for any progressive issues or development of disease the pre-existing murmur may mask.

**IMAGES**



The information and recommendations provided are based on the images presented by the referring veterinarian. No evaluation can be communicated regarding pathology that was not visible in the image/video clips provided.

Thank you for this referral. This report was generated using transcription software, and minor dictation errors may be present. If the clinical or image interpretation does not parallel your findings or if I can be of any further assistance, please contact me.

Maggie Machen Lamy, DVM  
Diplomate of the American College of Veterinary Internal Medicine (Cardiology)  
info@sonopath.com